



**PATIENT**

Zoe Beaudry

**SPECIES**

Canine

**BREED**

Minature Australian  
Shepherd

**SEX**

Female Spayed

**AGE**

2 years

**WEIGHT**

22lbs

**INTERPRETED BY**

Maggie Machen  
Lamy, DVM  
DACVIM (Cardiology)

**IMAGING  
PERFORMED BY**

Pamela Harrigan,  
RDCS

**HOSPITAL NAME**

Mass Veterinary  
Specialty Services

**REFERRING VET**

Dr. Masloski

**INVOICE**

21500

**DATE**

10/13/21

**PRESENTING CLINICAL SIGNS**

History: Recheck echo. History 2 episodes of abnormal mentation/lethargy at 1 year old. Presented to ER - bradycardia was found, which did increase with excitement. She received dose of lipids and IVF for presumptive toxicosis. ECG showed primarily sinus rhythm with periods of bradycardia. Echocardiogram (April 2020 at Tufts) showed all chambers to be slightly enlarged, possibly secondary to fluid therapy. A mild decrease in contractile function ? variation of normal for an athletic dog. Current presentation: Zoe continues to have collapse episodes. She tested positive for Lyme disease in October (elevated C6). Since her Holter (April 2020), Zoe has had a few collapse episodes. She seems to know when they are going to happen and will sit down in front of the fan. Her most recent episode was approximately 2 weeks ago when she collapsed going up the stairs. All of the episodes have occurred after playing/running/being in the sun or overheating- it takes approximately 15 minutes to recover. CV/RESP: NSR, no murmurs noted, PSS, lung fields clear. BP: 100mmHg x 5.  
-Current medications: Doxycycline 100mg 1 tab daily \*No sedation for study.  
-Holter results (4/2020 MML): Sinus bradycardia with occasional pauses and appropriate heart rate response to activity.

**ECHOCARDIOGRAM FINDINGS**

2D, m-mode, color flow and Doppler imaging is available.  
**Left ventricle:** The LV diameter is normal with adequate myocardial function. LV wall thicknesses are normal.  
**Left atrium:** The left atrium is normal.  
**Mitral valve:** The mitral valve is mildly thickened with no prolapse into the left atrial lumen. No mitral regurgitation.  
**Aortic valve/Aorta:** The aortic valve is normal in morphology and mobility. Normal aortic outflow velocity; laminar flow. No aortic insufficiency.  
**Right ventricle:** Normal right ventricular diameter and morphology indicating no overt evidence of pulmonary arterial hypertension.  
**Right atrium:** Normal RA dimension.  
**Tricuspid valve:** The tricuspid valve appears normal with no tricuspid regurgitation.  
**Pulmonic valve/Pulmonary artery:** The pulmonic valve is normal in morphology and mobility. No pulmonic insufficiency. Normal RVOT velocity; laminar flow.  
**Pericardium/other:** No pericardial or pleural effusion noted. No obvious cardiac masses.  
**Heart rhythm:** ECG reveals a sinus rhythm with an average HR of 110bpm.

**2-Dimensional Measurements**

Ao diam (cm)	1.5
LA diam (cm)	2.0
LA:Ao (Swe)	1.3
IVS thickness (cm)	0.77
LVID diastole (cm)	3.2
PW thickness (cm)	0.75
LVID systole (cm)	2.2
FS (%)	31

**Doppler Measurements**

PV Vmax (m/s)	0.72
AoV Vmax (m/s)	1.72
MR Vmax (m/s)	NA
TR Vmax (m/s)	NA
TR PG (mmHg)	NA

**INTERPRETATION OF THE FINDINGS**

Overtly normal cardiac structure and function. Previously documented four chamber dilation is not readily apparent in this study. The overall dimensions and function are largely normal for this body size with no significant valve leaks. Additionally, the systolic function appears adequate and no additional issues are identified.



**PATIENT**

Zoe Beaudry

**SPECIES**

Canine

**BREED**

Minature Australian  
Shepherd

**SEX**

Female Spayed

**AGE**

2 years

**WEIGHT**

22lbs

**INTERPRETED BY**

Maggie Machen  
Lamy, DVM  
DACVIM (Cardiology)

**IMAGING  
PERFORMED BY**

Pamela Harrigan,  
RDCS

**HOSPITAL NAME**

Mass Veterinary  
Specialty Services

**REFERRING VET**

Dr. Masloski

**INVOICE**

21500

**DATE**

10/13/21

These findings would rule out a structural cause for the episodes. The previous holter was largely unremarkable; however, an episode was not captured with the device in place. Options going forward include reassessing the holter with an attempt to capture an episode. Placement of an event monitor (likely available at Tufts), and/or use of a portal device at home. The goal of these options would be to definitively rule out an arrhythmic cause for the episodes. Other possibilities should of course also be considered. In this unusual case, management by a local Cardiologist may be ideal depending on client compliance.

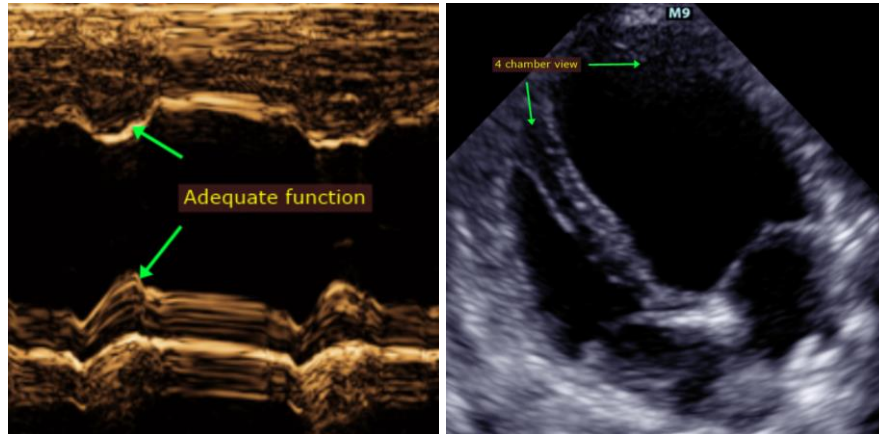
**RECOMMENDATIONS**

- No cardiac medications are indicated at this time.
- Consider repeat holter, event monitor placement, a AliveCor monitor, etc.
- Further systemic workup depending on clinical picture
- Consider referral as discussed.
- Monitor for any development of cough, labored breathing or exercise intolerance.

**PLAN**

- Recommend recheck echocardiogram in 12 months to ensure no progressive issues are identified

**IMAGES**



The information and recommendations provided are based on the images presented by the referring veterinarian. No evaluation can be communicated regarding pathology that was not visible in the image/video clips provided.

Thank you for this referral. This report was generated using transcription software, and minor dictation errors may be present. If the clinical or image interpretation does not parallel your findings or if I can be of any further assistance, please contact me.

**Maggie Machen Lamy, DVM**  
Diplomate of the American College of Veterinary Internal Medicine (Cardiology)  
info@sonopath.com

**Echocardiogram performed by:** Pamela Harrigan, RDCS  
Pet Animal Ultrasound Service (4paus.com)